

# Creation of an *Ex-vivo* Transjugular Intrahepatic Portosystemic Shunt (TIPS) Training Model Using a Perfused Non-cirrhotic Porcine Liver

Jorge E Lopera<sup>1\*</sup>, Ryan Bitar<sup>2</sup>, John Walker<sup>1</sup>, James Elliott<sup>3</sup>, Katie Strychalski<sup>3</sup>, Harrison Pollard<sup>2</sup>, Annie Dang<sup>2</sup>, Luis Garza<sup>2</sup>, Carlos Ortiz<sup>1</sup>, Matthew Parker<sup>1</sup>, Matthew Z Taon<sup>1</sup>, Partha Mandal<sup>1</sup>, Barrett O'Donnell<sup>1</sup>, Rajeev Suri<sup>1</sup>, Ho-Young Song<sup>1\*</sup>

<sup>1</sup>Department of Radiology, UT Health San Antonio, USA

<sup>2</sup>Long School of Medicine, UT Health San Antonio, USA

<sup>3</sup>Department of Lab Animal Resources, UT Health San Antonio, USA

\*Correspondence should be addressed to Jorge E Lopera; Lopera@uthscsa.edu

**Received date:** September 23, 2021, **Accepted date:** November 03, 2021

**Copyright:** © 2021 Lopera JE, et al. This is an open-access article distributed under the terms of the Creative Commons Attribution License, which permits unrestricted use, distribution, and reproduction in any medium, provided the original author and source are credited.

## Abstract

**Purpose:** To validate the feasibility of an *ex-vivo* flow model with explanted porcine livers for transjugular intrahepatic portosystemic shunt (TIPS) creation using different techniques. **Material and Methods:** Twenty porcine livers used for other non-related research were explanted after the animals were sacrificed. The inferior vena cava segments and portal vein were connected to vascular grafts. The portal vein graft was connected to a continuous 0.9% sodium chloride solution inflow by fountain pump. TIPS creation was performed under fluoroscopy alone (FL=9), transparenchymal ultrasound (US=3) or IVUS guidance (IVUS=10). Technical success was defined as patent shunt post creation. Technical difficulty was graded by procedural time in minutes as low (<20), moderate (20-30), and high (>30). The number of punctures, fluoroscopic time and radiation dose were compared by technique. **Results:** Twenty-one TIPS were successfully created including 2 parallel TIPS. One technical failure occurred in FL group. The mean fluoroscopy time and radiation dose were 20 minutes (range 9 to 65) and 102 mGy (range 15-430). Technical difficulty was low in 13 (5 FL, 2 US, 6 IVUS), moderate in 5 (5 IVUS) and high in 3 (2 FL, 1 US). IVUS guidance decreased number of punctures fluoroscopic time and radiation dose. **Conclusions:** Explanted livers can be used to create an *ex-vivo* flow model for TIPS procedures training. The model is reproducible with varying degrees of technical difficulty and amendable to various techniques.

**Keywords:** TIPS, Portal Hypertension, Cirrhosis

## Introduction

Liver cirrhosis is growing problem worldwide with serious adverse clinical manifestations secondary to portal hypertension, including ascites, hydrothorax, bleeding from gastric and esophageal varices among others [1]. Transjugular intrahepatic portosystemic shunt (TIPS) creation has demonstrated to be a very effective minimally invasive technique to treat portal hypertension largely supplanting surgical shunts. TIPS, however, is a highly technically demanding procedure with a steep learning curve [2].

Animal experiments with porcine and canine species were used to develop the original TIPS technique and are currently used for training and to test new devices [3,4]. The use of live animals for training is limited by ethical issues and the

high cost, the need for animal licenses, a dedicated animal facility and trained personnel including an anesthetist, and an operating room [5]. Synthetic models for TIPS simulation have been created using 3D printing, simulating variable human anatomy [6]. The high cost of these models and the lack of a realistic feel due to the issues with friction with the plastics, especially when trying to puncture the portal vein and advancing the stents and balloons through the tract, severely limits the utility of these models for TIPS training [5]. A TIPS virtual reality simulator is not available yet and lacks the realistic operator "feel" and force-feedback mechanisms of other models [7]. Having realistic models to train in the multiple steps of the procedure is very relevant for future interventional radiologist in order to become familiar with this technique, including needle bending, anterior vs. posterior punctures, and use of adjunct techniques including

Ultrasound (US) and Intravascular US (IVUS). Therefore, the purpose of this study was to create a low cost and reproducible ex-vivo perfusion model using explanted porcine livers, and demonstrate validate its use by comparing differences using various techniques.

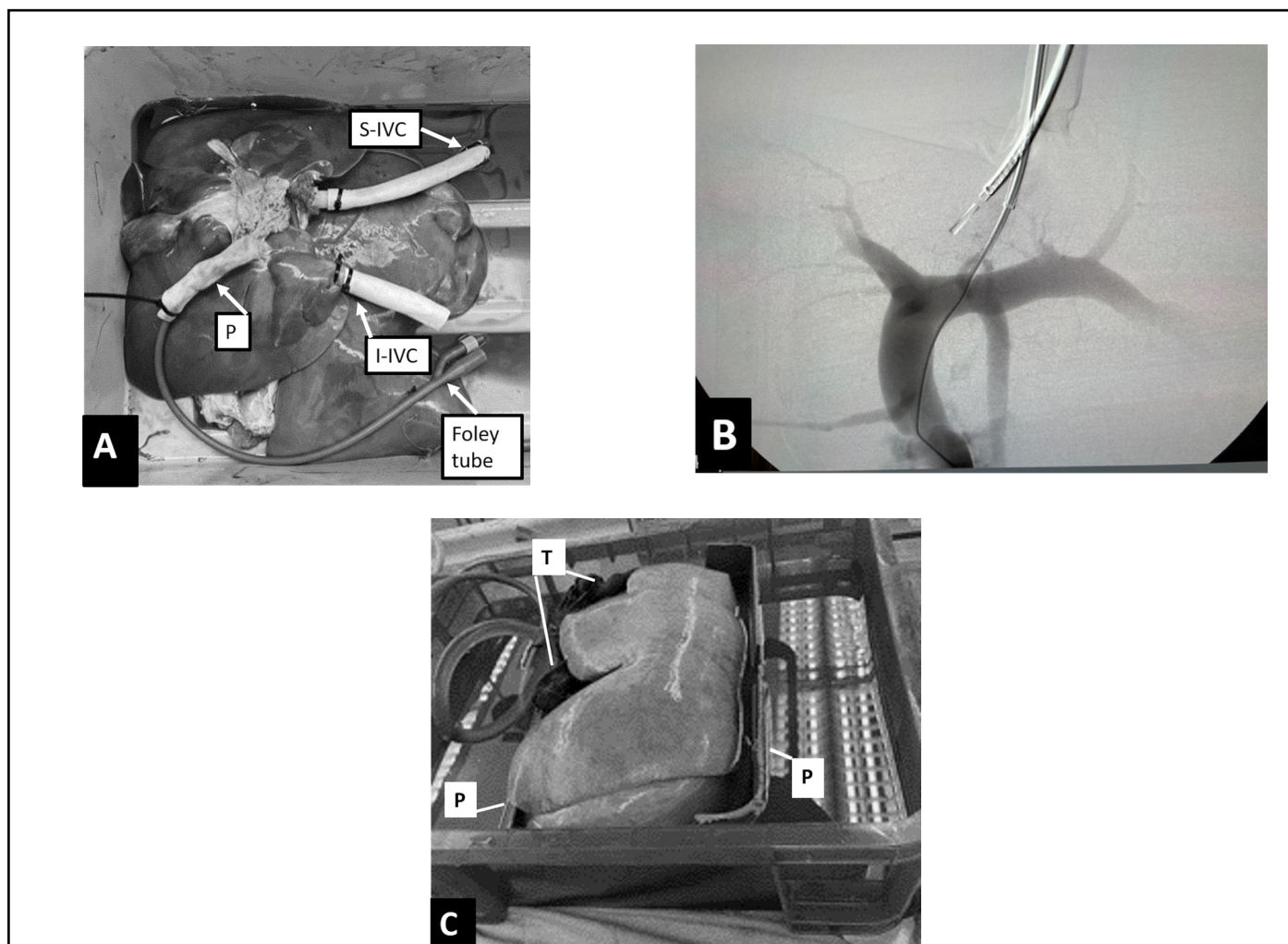
## Material and Methods

Twenty domestic adult healthy swine livers were harvested in the Animal Lab after the animals underwent other non-related research experiments and were sacrificed following institutional guidelines on euthanasia, dependent on the approved protocols. The livers were carefully dissected by a veterinarian and animal technician, preserving a 1-2-inch pedicle of the portal vein and 2-inch segments of infra and suprahepatic inferior vena cava (IVC). The portal vein was flushed with 500 cc of heparinized 0.9% sodium chloride solution and the livers were then frozen for 3-11 days until

the day of the experiment. Institutional Animal Care and Use Committee and IRB approvals were waived for this ex-vivo study.

### Model set up

On the day of the experiment, the livers were thawed with warmed 0.9% sodium chloride solution for 2 hours. The suprahepatic and infrahepatic IVC segments were connected to 18 mm × 40 mm pieces of vascular grafts (Goretex, Gore Medical, Flagstaff, AZ) using a 3/4 inch barb nylon splicer fitting purchased in hardware store and secured with zip ties avoiding the need for sutures. The portal vein was sutured to a 18 mm × 40 mm Goretex graft. A 24 Fr Foley catheter was inserted inside the portal graft and secured with a zip tie. The Foley catheter was connected to a Peaktop 256 gph fountain pump to provide the inflow Figure 1.



**Figure 1:** **A.** Photograph of the underside of the model, note grafts connected to the suprahepatic IVC (S-IVC), infrahepatic IVC (I-IVC) using barb adapters and zip ties. The portal vein is sutured to a graft. A Foley is inserted into the portal graft and secured with a zip tie. **B.** Diagram shows the set-up of the model. **C.** Photograph shows the model partially submerged in fluid. Note that the is liver engaged with plastic holders (P) and further lifted with towels (T).

The prepared liver was then placed inside a plastic basin partially filled with normal 0.9% sodium chloride solution until the pump was submerged in the fluid. The pump was turned on and the flow of fluid was inspected visually assessing that the portal graft became distended and that fluid flowed from the supra and infrahepatic segments into the basin. Any major leaks near the portal vein anastomosis were controlled by additional sutures when needed. Two 5 mm holes were drilled in the outer basin to allow passage of two parallel 16 Fr sheaths (Cook Medical, Bloomington, IN). Silicone sealant was used to fix the sheaths to the box and prevent leaks. These sheaths were then inserted inside the suprahepatic graft and secured by a zip tie. The livers flattened and dispersed on the basin resulting in collapse of the extra-hepatic veins. To circumvent this problem, plastic holders were used to secure the livers and towels were used to further lift the liver mimicking an *in-vivo* configuration Figure 1.

### TIPS procedures

The experiments were performed using an OEC 9900 C arm (GE Medical, Wauwatosa, WI). The procedures were performed by three interventional radiologists with 20, 15 and 5 years of clinical practice with extensive experience in TIPS, with the alternate assistance of two interventional radiology (IR) fellows, 3 IR/diagnostic radiology residents and 4 medical students.

A multipurpose catheter (Cook) was inserted via the superior approach into one of the hepatic veins, the most accessible vein that allowed advancement of the rigid metal cannula was selected. The infrahepatic IVC was usually horizontal in this model and could be differentiated from a hepatic vein by its larger caliber. A direct portogram was performed after the portal graft was punctured with a 18 G needle connected to a plastic tubing and 10-15 cc of dilute contrast medium (Omnipaque, GE) were injected by hand to visualize the anatomy and size of the portal vein, a road mapping imaging was used to direct the subsequent punctures. A Flexor 10 Fr sheath (Cook) was advanced into the hepatic vein. For the portal vein access, we used the Ring Transjugular Intrahepatic Access Set (Cook). Lateral portograms were also performed to determine the anterior or posterior direction for puncture planning in difficult cases. The Colapinto needle was advanced into the expected location of the portal vein and then slowly retracted while aspiration with a syringe was performed. When fluid was easily aspirated, contrast injection was performed to verify intraportal location. A Glidewire (Terumo Medical, Somerset, NJ) was manipulated into the portal vein graft under fluoroscopic guidance. A 5 Fr Kumpe catheter (Cook) was advanced into the portal vein and a portogram was performed. Amplatz superstiff wire (Cook) was then placed in the main portal vein and the tract was predilated with 5- or 6-mm balloons and a metallic stent was deployed between the main portal vein and the hepatic vein. Various stents were used, including balloon expandable and self-expandable

stents, depending on material availability. For the Viatorr stent graft (Gore Medical, Flagstaff, AZ), the 10 Fr Flexor sheath was advanced inside the portal vein and after the proximal 2 cm uncovered portion of the stent was deployed, the stent and sheath combination were retracted until resistance was felt at the parenchymal junction and then the covered portion of the stent was deployed. The stents were then post dilated with 5 to 8 mm balloons and a final portogram was obtained. Pressures were not obtained as this is not a portal hypertension model.

In three experiments, transparenchymal US was used to guide the punctures to the portal vein using a hand-held Butterfly probe (Guilford, CT) scanning from the anterior liver parenchyma. For IVUS guidance in the last 10 experiments, a second 10 Fr sheath was advanced through parallel 16 Fr sheath into the intrahepatic portion of the IVC. An 8Fr Acunav catheter (Acuson, Johnson and Johnson New Brunswick, New Jersey) was connected to a Vivid GE US machine. The probe was rotated until an in-line view of the hepatic vein and the portal vein was obtained. When using US or IVUS, portograms were not performed and the punctures were performed under direct visualization Figure 2.

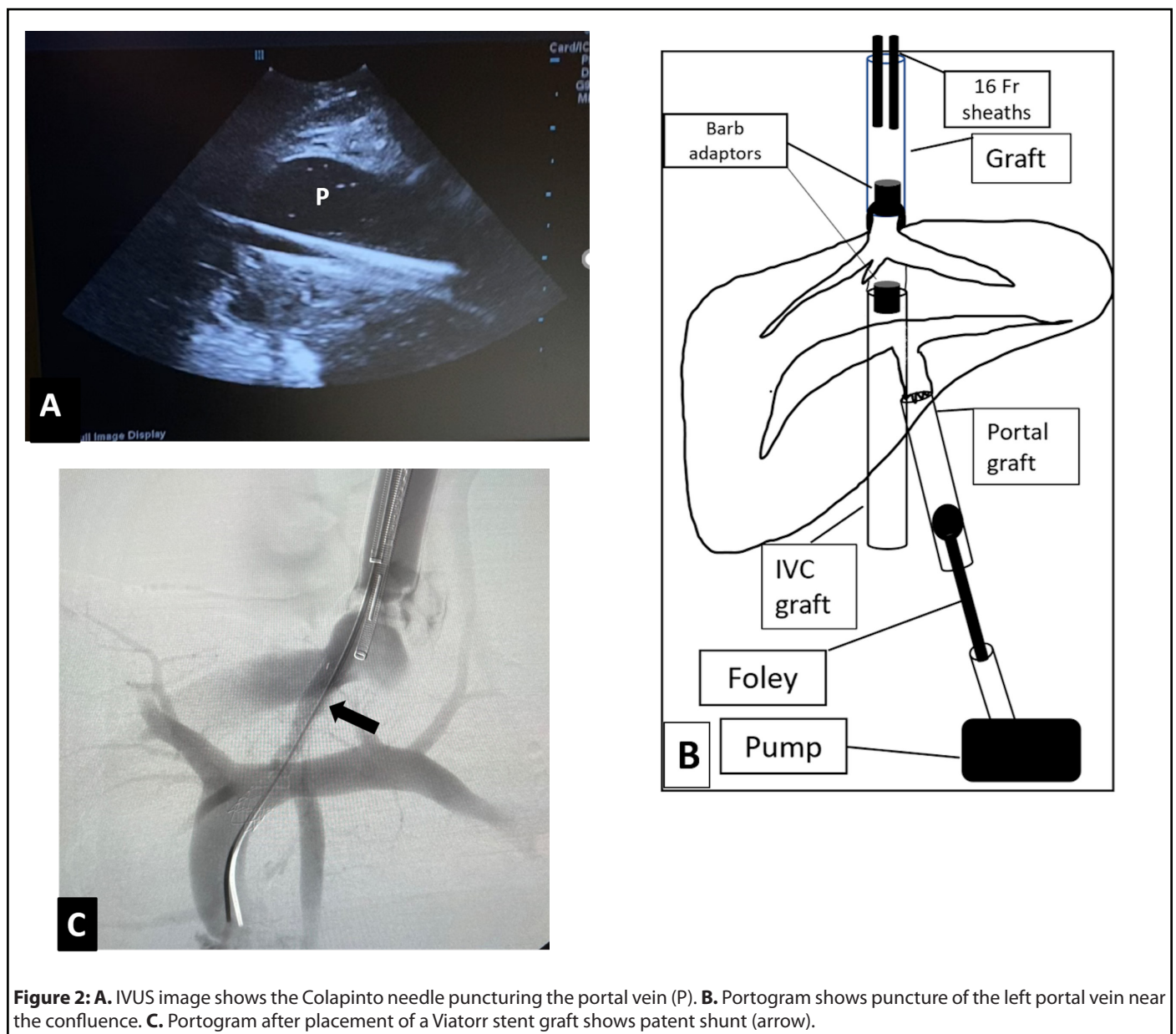
Technical success was defined as successful placement of a stent between the portal vein and hepatic vein with patent flow through the shunt in the final venogram. The total number of punctures was recorded. The total fluoroscopic time was recorded in minutes and radiation dose recorded in mGy. The technical difficulty was graded as low, if less than 20 minutes, moderate if 20-30 minutes, and high if over 30 minutes of fluoroscopy were required to complete the procedure. A negative binomial regression was used for comparing number of punctures. A Kruskal Wallis rank test was used for comparing time and dose. Statistical analysis was performed using Stata IC 11.2.

### Results

Details of the procedures are described in Table 1. Twenty-one TIPS were successfully created including 2 parallel TIPS performed in the IVUS group. There was one technical failure in the fluoroscopy group, despite multiple punctures, only a very peripheral branch of the left portal vein was accessed with inability to advance the wire into the main portal vein, US guidance was not available for that experiment and the procedure was abandoned after 32 minutes of fluoroscopy.

The technical difficulty was low in 13 (5 FL, 1 US, 6 IVUS), moderate in 5 (5 IVUS) and high in 3 (2 FL, 1 US). For all procedures the mean number of punctures was 7 (range 1-40), fluoroscopy time 21 minutes (range 9-65) and radiation dose were 102 mGy (range 15-430). The median number of punctures were significantly lower in the IVUS group when compared to fluoroscopy alone group, 3 (1 - 10) vs 6 (3-40),  $p = 0.0008$ . When using IVUS the fluoroscopy time and radiation dose were less than using fluoroscopy alone,  $16 \pm 7$  minutes





**Table 1:** Details of the procedures.

	Stent type Diameter/Length	Number of punctures	Puncture site	Technique	FLuoro time min	Cumulative dose mGy
1	Viabahn 6 × 5	22	Confluence	FLuoro	65	240
2	Viabahn 6 × 5	6	Left portal	FLuoro	18	89
3	Wallstent 10 × 42	4	Left portal	FLuoro	15	51
4	Viatorr 8 × 6	3	Confluence	FLuoro	10	38
5	Viatorr 10 × 6	13	Confluence	FLuoro	41	171
6	Wallstent 10 × 68	3	Confluence	FLuoro	9	33
7	Viatorr 8 × 6	6	Right portal	FLuoro	10	49
8	Wallstent 10 × 68	21	Right portal	FLuoro	33	430

9	Failed	40		Fluoro	32	348
10	Viatorr 10 × 7	3	Confluence	US	17	94
11	VBX 6 × 29 (2)	4	Left portal	US	31	98
12	Viabahn 6 × 5	1	Left portal	US	13	43
13	Viatorr 8 × 5	5	Left portal	IVUS	25	81
14	Viatorr 8 × 5	5	Left portal	IVUS	25	81
15	Fluency 6 × 8	1	Right portal	IVUS	11	25
16	Smart 10 × 8	10	Right portal	IVUS	21	77
17	Viatorr 10 × 8	2	Confluence	IVUS	15	55
18	VBX 5 × 29 (2)	3	Right portal	IVUS	19	98
19	Viabahn 11 × 5	3	Confluence	IVUS	20	90
20	Viator 8 × 6 Parallel	1	Right portal	IVUS	6	16
21	Viabahn 11 × 10	3	Right portal	IVUS	20	65
22	Wallstent 12 × 60 Parallel	1	Right portal	IVUS	15	61
23	Viabahn 11 × 5	1	Right portal	IVUS	4	15

Fluoro: Fluoroscopy; US: Ultrasound; IVUS: Intravascular Ultrasound

and  $60 \pm 30$  mGy vs  $26 \pm 19$  minutes and  $161 \pm 148$  mGy respectively, however, these values did not reach statistical difference.

The stents deployed included 8 Viatorr stent grafts, 4 Wallstents (Boston Scientific, Natick, MA), 6 Viabahn (Gore), 2 VBX stent grafts (Gore), one Fluency (BD, Franklin Lakes, New Jersey) and one Smart non covered stent (Cordis, Santa Clara, CA). All shunts were patent at the end of the procedures with no instances of stent migration or misplacement.

## Discussion

TIPS is one of the most complex, technically demanding and radiation intensive procedures in IR [2,8]. The initial puncture of the portal vein can be very challenging as the relationship of the hepatic veins with the portal vein is not always constant and it can be further altered in advanced cirrhosis. Accessing the portal vein under fluoroscopy is mostly a blind step and it can require multiple punctures increasing the risk of complications. The use of transabdominal US and IVUS have greatly facilitated the procedure in challenging cases, reducing the number of punctures and fluoroscopic time [2,9,10]. Adequate experience is particularly important in TIPS given its complexity. The overall success rate of TIPS varies between 84–100%. In skilled hands the technical success rate of TIPS is over 95% with higher technical failure rates in institutions that have performed less 100 TIPS procedures [11,12]. A lower incidence of fatal procedural complications was reported in institutions with more experience (1.4%), than those with less than 150 cases (3%) [11,13]. Others studies support that one of the main factors in the duration of the procedure is the clinical

experience and skill level of the operator [13].

TIPS training has been traditionally done as part of formal fellowship clinical process with patients. This form of training has both legal and patient safety issues, and many centers may not have the volume of TIPS procedures to provide adequate training to the fellows [5]. Animals' models have been used but are limited by ethical and logistic issues and are very expensive. 3D printed liver models may provide an alternative as the anatomy of the veins can be modified, these models are relatively expensive and the materials used for the models still lack a realistic feel for the operators [5]. We described the successful creation of low-cost perfusion model using explanted livers obtained from our animal Laboratory after other non-related research projects were completed. Using this model our technical success for TIPS creation using different imaging guidance techniques was 95%. This study shows the potential of using this model to train residents and fellows in the multiple steps of a TIPS procedure in a low-risk environment with lower cost than other animal models.

In this study there was a high variability in the technical complexity of the procedures resulting in fluoroscopic times as short as 6 minutes or as long as 65 minutes. The mean fluoroscopy time of 21 minutes was lower than ranges of 32–78 minutes of fluoroscopy reported in patients [8,13,14]. As reported in clinical studies, the use of US guidance proved to be very useful to guide the portal puncture [10]. Transparenchymal US was used in 3 and IVUS guidance in 10 procedures with no technical failures. The use of IVUS was possible by submerging the liver in fluid to decrease the air interfaces between tissues. IVUS decreased the number

of punctures, radiation time and number of extracapsular punctures. The additional steps that are used in IVUS such as manipulating the probe in order to obtain an in-line view of the needle and puncturing the portal vein under direct visualization, were possible in this model and it could provide additional training opportunities for the fellows and residents to become familiar with this emerging technique.

As the livers were free from any surrounding soft tissues, the model had a variable position of the veins that affected the relationship of the portal vein and the hepatic veins. Although the cannulation of the hepatic veins was relatively easy, the punctures of the portal vein were more difficult than a live swine model. We performed a direct portogram by puncturing the portal graft, this was done to simulate the wedge CO<sub>2</sub> portogram performed in patients, and it was very useful to guide the portal puncture, especially when combining with a lateral portogram. Some procedures required further bending the Colapinto needle or using a different hepatic vein, situations that are also encountered in a real TIPS procedure. As the model has a constant flow of fluid provided by the pump, aspiration of fluid was possible when the portal vein was successfully punctured. Also, injections of contrast were possible to visualize the anatomy after the punctures and confirm adequate placement and patency of the shunts. Extracapsular punctures were also identified as contrast extravasating into the basin. After the main portal vein was cannulated, the other steps of the procedure were reproducible. The additional and unique steps of the Viatorr system deployment were possible, including advancing the 10 Fr sheath inside the main portal vein, deploying the uncovered portion of the stent graft inside the main portal vein, and retracting the system until resistance was felt at the parenchymal junction. Using this model, we successfully deployed the Viatorr stent grafts in 6/6 livers with the transition part between the covered and non-covered portion in adequate position in all experiments Figure 2.

In our practice the cost of the model was low as the livers were donated by other researchers at no expense. The vascular grafts, IVUS catheter, TIPS sets, wires and balloons were reused for the experiments. The stents were unused expired materials. The materials that were purchased included the submersible fountain pump (\$25), the plastic box (\$20) and the barb adaptors (\$ 5).

Our study has several limitations. The livers need be carefully harvested after the animal is sacrificed in order to preserve an adequately long pedicle of portal vein and infra and suprahepatic IVC. The availability of livers from other research projects and the assistance of the veterinarian team may be not feasible in other centers. Another limitation is that as the liver is not supported by surrounding tissues, there is a variable position of the portal vein in relationship to the hepatic veins that made the initial puncture of the portal branch difficult, increasing the technical complexity of the model, especially

using fluoroscopy guidance only. Lastly the liver anatomy of the swine is not only different than the human but we also used normal non cirrhotic livers which further differentiated this model from a TIPS procedure in a patient. We are currently working in a model that better simulates the consistency of a cirrhotic liver using special preservation techniques of the organs.

In conclusion we describe the creation of a reproducible TIPS model using explanted porcine livers. This model was able to successfully incorporate various imaging techniques—including fluoroscopy alone, transparenchymal US, and IVUS—and serves as a hybrid between a synthetic and live animal model. The cost of the model is significantly lower than using live animals allowing for simulation of parenchymal punctures, balloon dilation and stent placement, with less resistance and a more realistic “feel” than plastic models. The flow in the model simulates live venous circulation with the ability to aspirate fluid confirming portal vein puncture and perform post TIPS creation portograms to assess adequate placement of the stents and shunt patency. Future validation of the utility of the model as a training educational tool for TIPS placement is required, with objective goals to measure the fidelity and full procedure simulation of the system.

## Declarations

- The authors did not receive support from any organization for the submitted work.
- All authors certify that they have no affiliations with or involvement in any organization or entity with any financial interest or non-financial interest in the subject matter or materials discussed in this manuscript.
- This study was IRB and IACUC exempted.

## Funding

Training support for A.D. was funded by the South Texas Medical Scientist Training Program (NIH T32GM113896).

## References

1. Hung ML, Lee EW. Role of transjugular intrahepatic portosystemic shunt in the management of portal hypertension: review and update of the literature. *Clinics in Liver Disease.* 2019 Nov 1;23(4):737-54.
2. Miraglia R, Maruzzelli L, Cortis K, D'Amico M, Florida G, Gallo G, et al. Radiation exposure in transjugular intrahepatic portosystemic shunt creation. *Cardiovascular and Interventional Radiology.* 2016 Feb 1;39(2):210-7.
3. Rösch J, Hanafee W, Snow H, Barenfus M, Gray R. Transjugular intrahepatic portacaval shunt an experimental work. *The American Journal of Surgery.* 1971 May 1;121(5):588-92.
4. Palmaz JC, Sibbitt RR, Reuter SR, Garcia F, Tio FO. Expandable intrahepatic portacaval shunt stents: early experience in the dog.

American Journal of Roentgenology. 1985 Oct 1;145(4):821-5.

5. Ahmed K, Keeling AN, Fakhry M, Ashrafian H, Aggarwal R, Naughton PA, et al. Role of virtual reality simulation in teaching and assessing technical skills in endovascular intervention. *Journal of Vascular and Interventional Radiology.* 2010 Jan 1;21(1):55-66.

6. Javan R, Zeman MN. A prototype educational model for hepatobiliary interventions: unveiling the role of graphic designers in medical 3D printing. *Journal of Digital Imaging.* 2018 Feb;31(1):133-43.

7. Coates PJ, Zealley IA, Chakraverty S. Endovascular simulator is of benefit in the acquisition of basic skills by novice operators. *Journal of Vascular and Interventional Radiology.* 2010 Jan 1;21(1):130-4.

8. Zweers D, Geleijns J, Aarts NJ, Hardam LJ, Lameris JS, Schultz FW, et al. Patient and staff radiation dose in fluoroscopy-guided TIPS procedures and dose reduction, using dedicated fluoroscopy exposure settings. *The British Journal of Radiology.* 1998 Jun;71(846):672-6.

9. Kao SD, Morshedi MM, Narsinh KH, Kinney TB, Minocha J, Picel AC, et al. Intravascular ultrasound in the creation of transhepatic portosystemic shunts reduces needle passes, radiation dose, and procedure time: a retrospective study of a single-institution experience. *Journal of Vascular and Interventional Radiology.* 2016

Aug 1;27(8):1148-53.

10. Tavare AN, Wigham A, Hadjivassilou A, Alvi A, Papadopoulou A, Goode A, et al. Use of transabdominal ultrasound-guided transjugular portal vein puncture on radiation dose in transjugular intrahepatic portosystemic shunt formation. *Diagnostic and Interventional Radiology.* 2017 May;23(3):206-210.

11. Keller FS, Farsad K, Rösch J. The transjugular intrahepatic portosystemic shunt: technique and instruments. *Techniques in Vascular and Interventional Radiology.* 2016 Mar 1;19(1):2-9.

12. Barton RE, Rösch J, Saxon RR, Lakin PC, Petersen BD, Keller FS. TIPS: short-and long-term results: a survey of 1750 patients. *In Seminars in Interventional Radiology* 1995 Dec (Vol. 12, No. 04, pp. 364-367). Copyright© 1995 by Thieme Medical Publishers, Inc.

13. Marquardt S, Rodt T, Rosenthal H, Wacker F, Meyer BC. Impact of anatomical, procedural, and operator skill factors on the success and duration of fluoroscopy-guided transjugular intrahepatic portosystemic shunt. *Cardiovascular and Interventional Radiology.* 2015 Aug;38(4):903-12.

14. Miller DL, Kwon D, Bonavia GH. Reference levels for patient radiation doses in interventional radiology: proposed initial values for US practice. *Radiology.* 2009 Dec;253(3):753-64.